



PATIENT

Lacy Pentzek

PRESENTING CLINICAL SIGNS

vomiting, lethargic for a two days.
Abnormal PE/Chem/CBC/UA Results: white blood cells low.

SPECIES

Canine

RADIOGRAPHIC STUDY OF THE ABDOMEN

Radiographs of the abdomen in three imaging planes are provided for review.

BREED

Shih Tzu Mix

RADIOGRAPHIC FINDINGS

The surrounding bony structures are within normal limits.

SEX

Female Spayed

No abnormalities of the extraabdominal soft tissues are noted. The abdominal wall is smooth and thin.

The serosal detail is maintained throughout the peritoneal and retroperitoneal space.

AGE

9 Years

The liver is appropriate in position, size and presents uniform opacity.

The splenic head is in the anticipated position and within normal limits for size and opacity. The splenic body and tail are considered normal for position, size, shape and opacity.

INTERPRETED BY

Sebastian Schaub, DVM
Dr. med. vet. DipECVDI

Both kidneys are seen and present with normal size, shape, delineation and opacity. The urinary bladder is in its anticipated position. No radiopaque calculi are noted throughout the upper and lower urinary tract.

The stomach is in its anticipated position and is empty but a mild amount of gas – contrasting mildly prominent gastric rugal folds.

HOSPITAL NAME

St. Catherine's Animal
Hospital

The small intestinal loops are of even diameter and non-dilated, a small amount of gas is seen within the small intestinal loops and considered within normal limits.

The colon is seen in the expected position and presents with appropriate content.

REFERRING VET

Dr. Mena

RADIOGRAPHIC DIAGNOSIS

- Empty stomach with subjective mild thickening of the rugal folds

INTERPRETATION OF THE FINDINGS & FURTHER RECOMMENDATIONS

INVOICE

51306

The subjectively mild prominent rugal folds can indicate gastritis. There is no evidence of radiopaque foreign material or signs for gastrointestinal mechanical obstruction. If clinical signs are refractory to empirical therapy, recommend follow up radiographs or a complete abdominal ultrasound examination; in some cases, a high ileus may lack classical radiographic signs of mechanical obstruction.

DATE

4-1-22



PATIENT

Lacy Pentzek

SPECIES

Canine

BREED

Shih Tzu Mix

SEX

Female Spayed

AGE

9 Years

INTERPRETED BY

Sebastian Schaub, DVM
Dr. med. vet. DipECVDI

HOSPITAL NAME

St. Catherine's Animal
Hospital

REFERRING VET

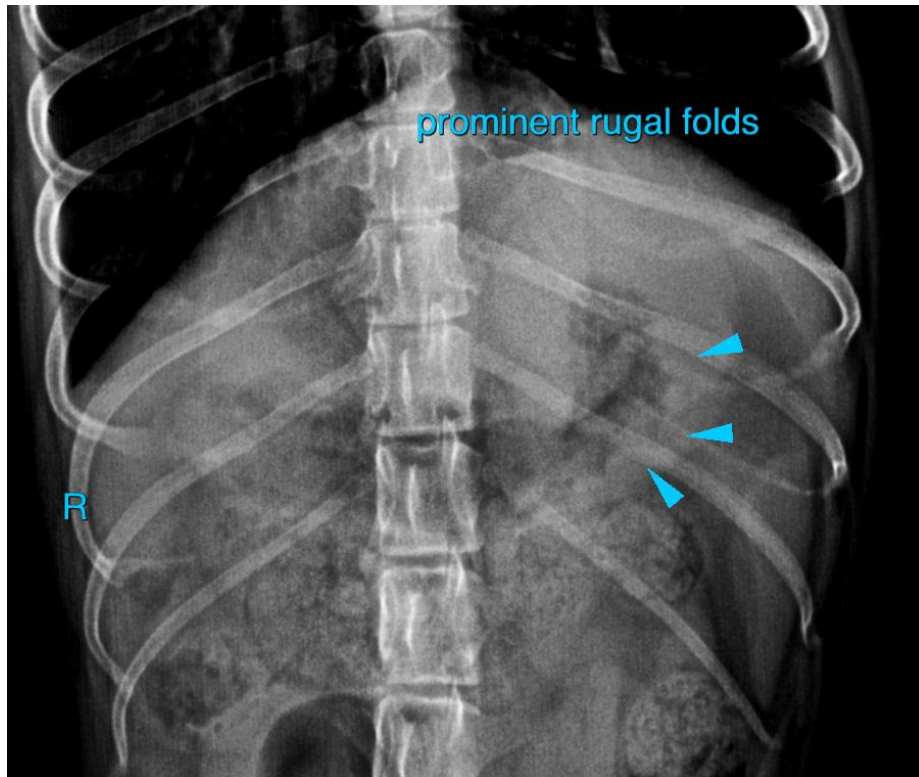
Dr. Mena

INVOICE

51306

DATE

4-1-22



The information and recommendations provided are based on the images presented by the referring veterinarian/sonographer. No evaluation can be communicated regarding pathology that was not visible in the image/video clips provided.

Thank you for this referral. If the clinical or image interpretation does not parallel your findings or if I can be of any further assistance please contact me.

Sebastian Schaub, Sebastian Schaub, DVM, Dr. med. vet. DipECVDI
sebast.schaub@gmail.com